

Image Guided Cardiac Surgery

NHLBI/AATS Cardiothoracic Surgery Symposium & Workshop

Keith A. Horvath, MD



Imaging Tools

Modality	Spatial Resolution	Tissue penetration	Differentiate tissue boundaries	Soft Tissue characteristics	Energy source	Real-Time	Ionizing radiation
X-ray fluoroscopy	++	++++ Complete	++	++ Semi-transparent	External	yes	yes
CT	+++	++++ Complete	+++	++	External	+/-	yes
MRI	+++	++++ Complete	+++++	+++++	External	+/-	no
Ultrasound	+	+++ No bone; 2-20 cm	+++	+++	External/ Tool tip	yes	no
Optical	+++++	++ ≤5 mm	+++++	++	Tool tip	yes	no

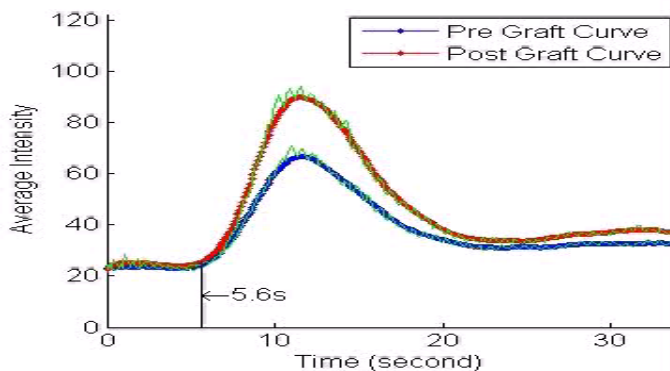
Physiologic Imaging in Revascularization

Full Phase Angiography

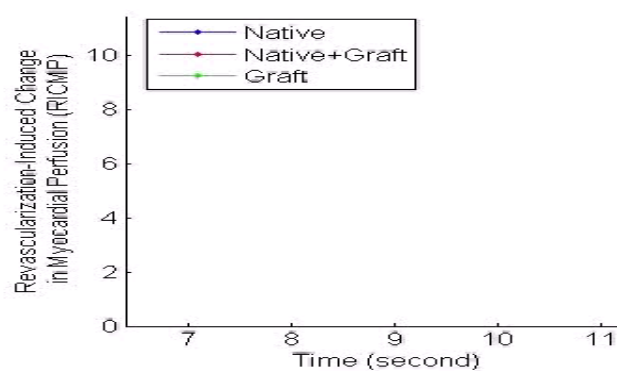
Myocardial Perfusion

Quantification

Synchronization of Image Loops



Accumulative Area and Intensity



Pre Graft Image



Post Graft Image



Image Fusion with Registration

- Act of aligning two images
- Segmentation/separation of a digital image into areas based on thresholding criteria
- Reconstruction of structure of interest
- Alignment via fiducial points

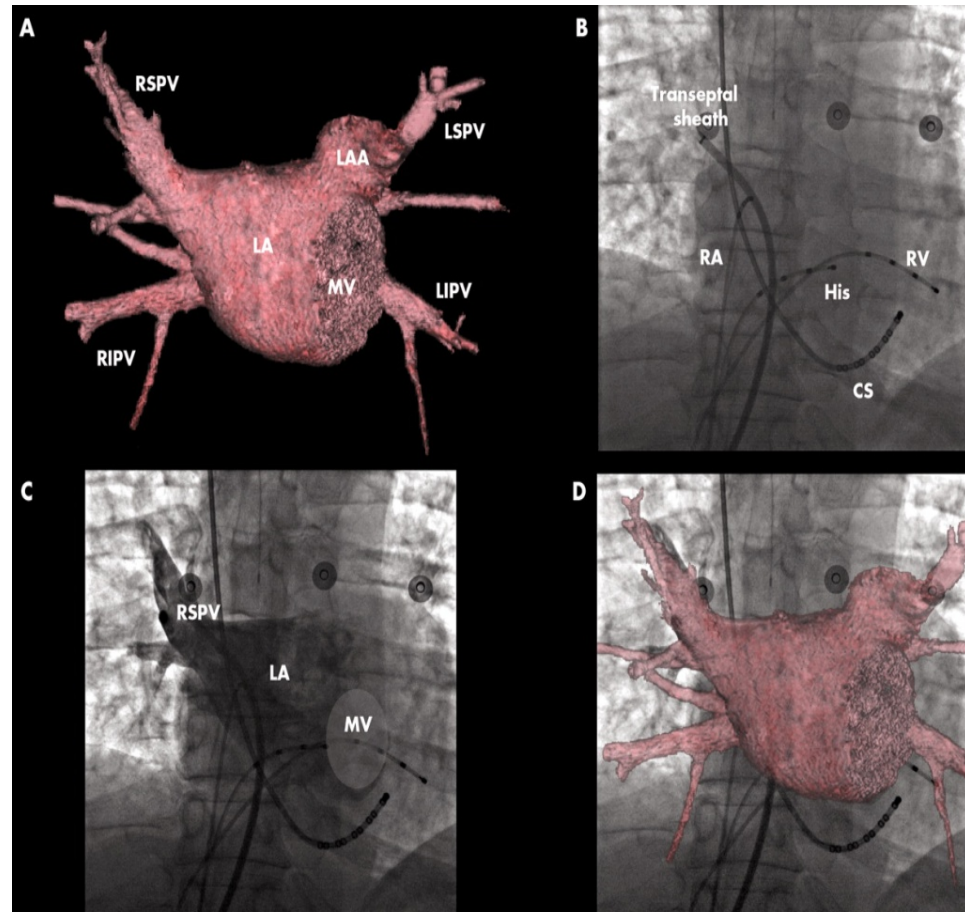
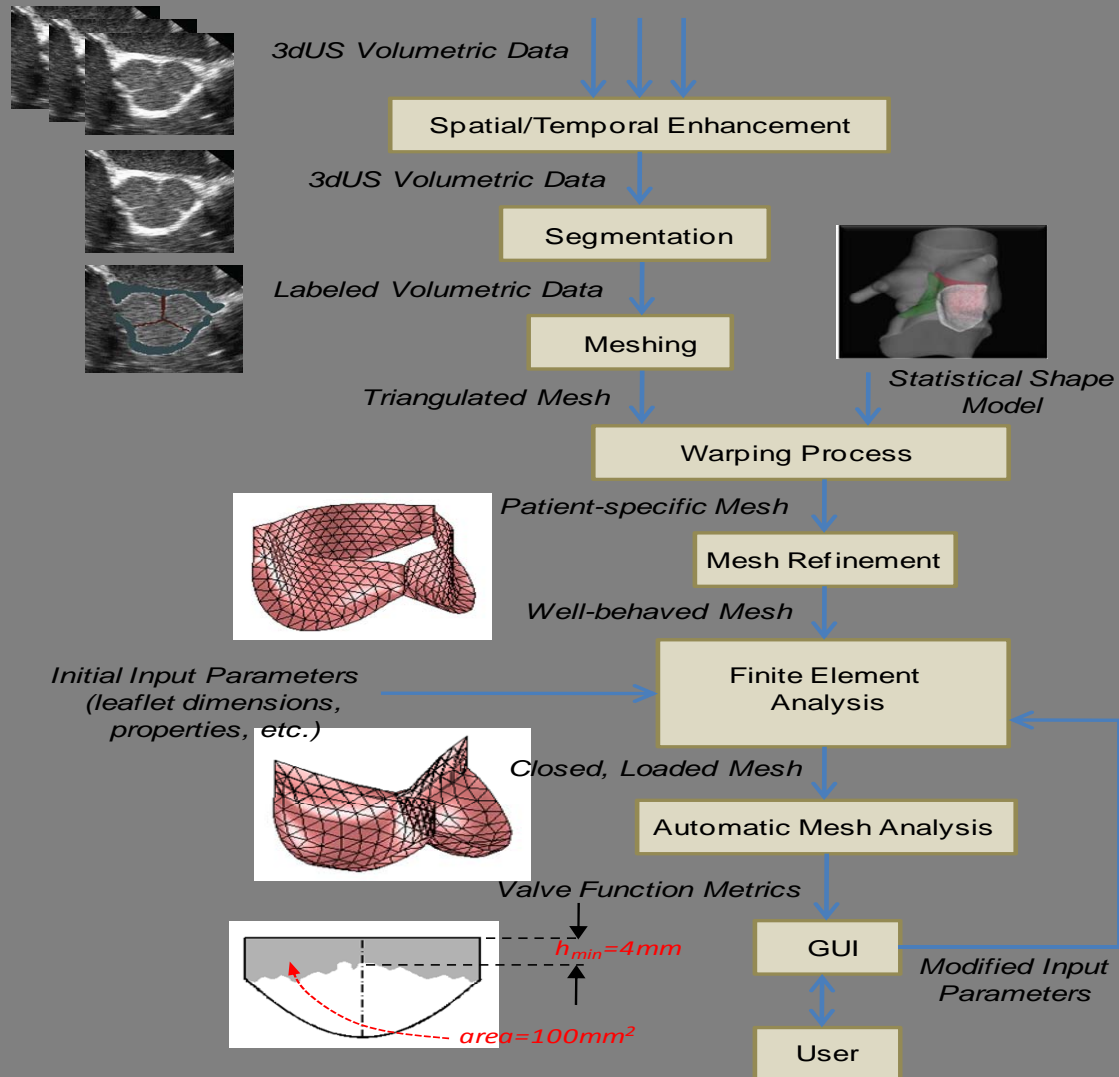



Image Based Modeling

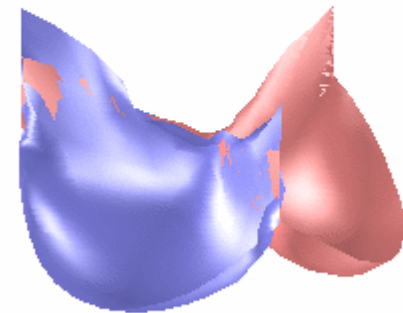
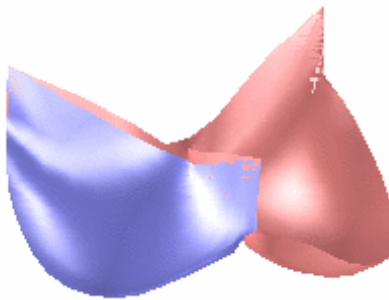


Computer Simulation for Valve Repair

Normal Aortic Valve



Repair: Pericardial Autograft



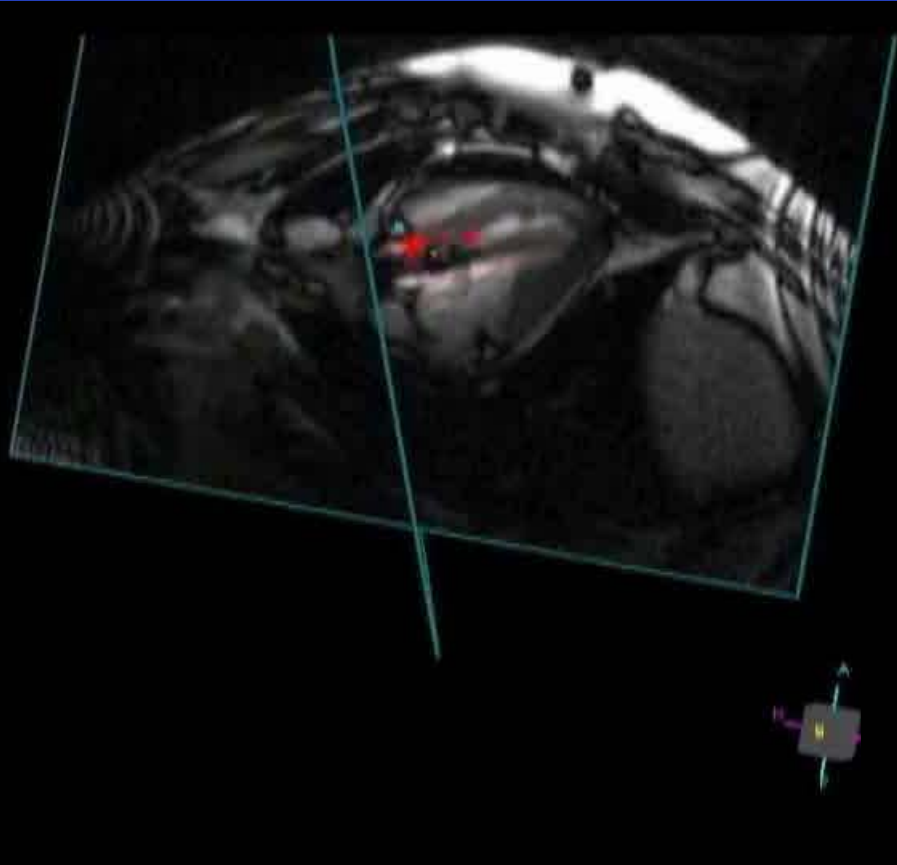
Repair: Same Size

Repair: Optimal Size

Width + 20%

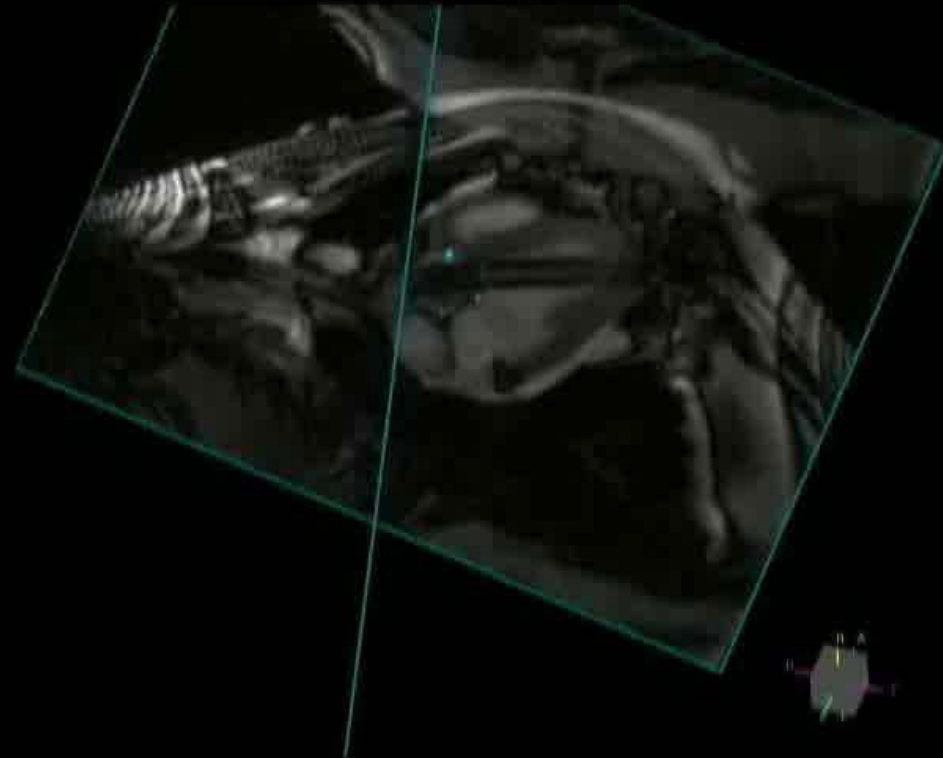
Height + 25%

Real-time MRI Guided AVR



Active Marker

77 ± 9 seconds



Passive Marker

Imaging Conclusions

Major Gap

- Move imaging from diagnostic to therapeutic role

Major Challenge

- Make imaging fit the therapy not vice versa